

Brainstem shape is affected by clinical course in the neonatal intensive care unit



Marcus Lo^{a,*}, Leire Zubiaurre-Elorza^{a,b}, Conor Wild^a, Annika C. Linke^a, David S.C. Lee^c, Victor K. Han^c, Rhodri Cusack^{a,c}

^a Brain and Mind Institute, Western University, London, Canada

^b Department of Methods and Experimental Psychology, Faculty of Psychology and Education, University of Deusto, Bilbao, Spain

^c Children's Health Research Institute, London, Canada

ARTICLE INFO

Keywords:

Perinatal
Brainstem
Magnetic resonance imaging (MRI)
Preterm birth
Neonatal intensive care unit (NICU)

ABSTRACT

The brainstem, critical for motor function, autonomic regulation, and many neurocognitive functions, undergoes rapid development from the third trimester. Accordingly, we hypothesized it would be vulnerable to insult during this period, and that a difficult clinical course in the neonatal intensive care unit (NICU) would affect development, and be reflected through atypical shape. Our study population consisted of 66 neonates – all inpatients from the NICU at Victoria Hospital, London Health Sciences Centre, ON, Canada, of which 45 entered the final analysis. The cohort varied in gestational age (GA) and ranged from neurologically healthy to severely brain-injured. Structural MRI was used to quantify brainstem shape at term-equivalent age. From these images, brainstems were semi-automatically segmented and co-registered across subjects. The anterior-posterior dimensions on a sagittal maximum intensity projection were used as the basis for shape comparison. Factor analysis was used to summarize variation in shape and in clinical course to determine three shape factors and three clinical factors, and their relationship assessed using correlation. A factor driven by low GA and associated complications correlated with alterations in the posterior medulla, while a factor driven by complications independent of GA correlated with alterations in the midbrain. Additionally, single clinical measures most representative of their respective clinical factor (days in NICU; days on ventilation) predicted the changes. Thus, different clinical courses in the NICU may have different effects on the shape of the brainstem, and may mediate some of the distinct neurodevelopmental profiles observed in premature and brain-injured neonates.

1. Introduction

The brainstem plays a pivotal role in brain function and is critical for survival, regulating processes including rhythmic breathing, blood pressure, and sleep cycles (Cohen 1979; Guertzenstein and Silver 1974; Hobson et al. 1975). Stimulation to the brainstem has also been shown to elicit complex goal-oriented behavior, and has been further implicated in controlling locomotion associated with behavioral responses to rewarding or aversive stimuli (Berntson and Micco 1976; Drew et al. 2004). It also serves as an important relay station for cortical signals, and is innervated by the auditory, visual, and motor networks. Improper regulation or interruption of any of these functions can result in severe consequences.

Indeed, adverse neurodevelopmental outcomes are an established risk of perinatal insult (Jiang et al. 2009; Nosarti et al. 2014, 2008; Payne et al. 2013; Vohr et al., 2000; White et al. 2014). In response,

there is strong interest in understanding the consequences that arise from premature birth and perinatal brain injury. Better measurement of the anatomical alterations that result from these insults might provide improved diagnostic markers, and elucidate the mechanisms through which brain function is affected – guiding intervention and reducing future cognitive and behavioral impairments.

During gestation, the third trimester is particularly important for brainstem development, and it undergoes rapid developmental changes during this period (Darnall et al. 2006; Geva and Feldman 2008; Hüppi et al. 1998). As such, the brainstem may be particularly vulnerable to insult at this time.

Past studies concerning the negative effects of prematurity and brain injury on brainstem structure have primarily discussed structural alterations in terms of visible size differences and volumetric alterations (Barkovich and Sargent 1995; Messerschmidt et al. 2008; Mewes et al., 2006; Padilla et al. 2015). Shape changes resulting from these insults

Abbreviations: FA, Flip angle; GA, Gestational age; NICU, Neonatal intensive care unit

* Corresponding author at: Brain and Mind Institute, Western University, London, ON N6A 5B7, Canada.

E-mail address: mlo53@uwo.ca (M. Lo).

<http://dx.doi.org/10.1016/j.nicl.2017.04.007>

Received 7 December 2016; Received in revised form 28 March 2017; Accepted 11 April 2017

Available online 12 April 2017

2213-1582/ © 2017 The Authors. Published by Elsevier Inc. This is an open access article under the CC BY-NC-ND license (<http://creativecommons.org/licenses/by-nc-nd/4.0/>).

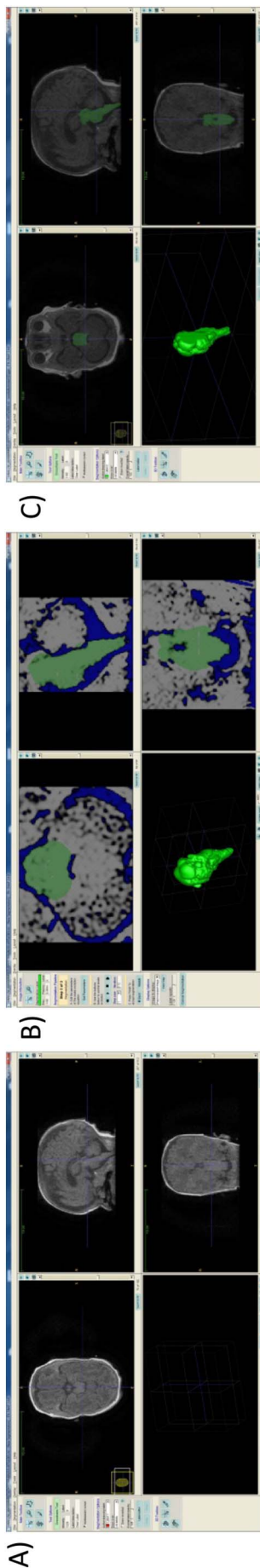


Fig. 1. (A) Original unprocessed T1-weighted MRI. (B) Output after pre-segmentation phase and active contour phase. Foreground regions (regions of interest) are white. Background regions are blue. The green regions depict the result of automatic seed expansion within the regions of interest. The unedited 3D output can be seen bottom-left. (C) Final manually-edited output of brainstem segmentation. (For interpretation of the references to colour in this figure legend, the reader is referred to the web version of this article.)

have not been well documented, and remain poorly understood. Recently, there has been one study investigating changes in brainstem shape resulting from prematurity in a cohort of 8 year-old children born preterm (Garg et al. 2016). Another study has also anecdotally noted a pattern of reduced anterior-posterior dimensions on sagittal projections of the brainstem in 2 month–2 year old children born preterm (Messerschmidt et al. 2005). To our knowledge, however, there are no studies directly measuring the effect of prematurity and perinatal brain injury on brainstem shape in neonates, and this was the goal of the present study.

In this report, structural MRI was used to measure the anatomy of the brainstem in infants from the neonatal intensive care unit (NICU). Past studies have shown abnormalities in brainstem function in neonates under intensive care (Jiang et al. 2012, 2013). We hypothesized a link between intensive care and brainstem structure as well, and that certain aspects of the clinical course would affect the shape of the brainstem in structures quantifiable on sagittal projections – namely the medulla, the midbrain, and the pons.

2. Methods

2.1. Cohort

Sixty-six inpatients were recruited from the NICU at Victoria Hospital, London, ON, Canada. The subjects spanned from 24 to 41 weeks gestational age (GA), and ranged from neurologically healthy to severely brain-injured. Parents were invited to participate in this research study if their infant met the following inclusion criteria: requirement for a clinical MRI, as determined by the neonatology and neurology team at Victoria Hospital, London, Canada, and fulfillment of the criteria to be enrolled in the Canadian Neonatal Follow-Up Network: being born < 29 weeks GA, or being at elevated risk of neurodevelopmental complications (e.g. secondary to asphyxia during birth). Infants with ferromagnetic implants of any sort were excluded. The infant's caregiver signed informed consent. Ethical approval was obtained from the Health Sciences Research Ethics Board of Western University.

2.2. Magnetic resonance imaging

All subjects underwent a T1-weighted MRI scan (GE MR 450W, 1.5T scanner, 3D SPGR sequence TE = 4.2 ms, TR = 8.4–11.5 ms, FA = 12/25°, matrix size 512 × 512, 99–268 slices, voxel size typically 0.39 × 0.39 × 0.5 mm) during unsedated natural sleep at term-equivalent age at Victoria Hospital. Infants were wrapped in a MedVac vacuum blanket to minimize motion, and wore infant ear protection (MiniMuffs, Natus, 7 dB attenuation) and ear defenders (29 dB attenuation, <http://www.scansound.com/index.php/mri-noise-reduction-headphone.html>). During scanning sessions, infants were monitored by an attending NICU nurse using pulse-oxymetry, electrocardiogram, and a noise-cancelling microphone (FOMRI-III, Optoacoustics) attached to the head coil.

Of the $N = 66$ MRI scans obtained, 9 were corrupted due to participant motion and 2 failed automatic inter-subject brainstem registration (described later). This left 55 usable brainstem images. Of these, however, full clinical data (details in Supplementary Table) was available for $N = 45$. This is the final sample used in the analyses.

2.3. Semi-automatic segmentation

T1-weighted structural MRI images were semi-automatically segmented to isolate the brainstem. ITK-SNAP (<http://www.itksnap.org/>) is a software tool used to render medical images in 3D. It is a reliable and efficient alternative to the traditional method of manual tracing on slices, which is prone to error and user bias (Yushkevich et al. 2006).

ITK-SNAP v.2.4.0 was used to perform the segmentations in the




Fig. 2. The 3D output of all brainstems ($n = 55$) after semi-automatic segmentation with ITK-SNAP. Two brainstems failed registration during principal components analysis, and were omitted.

study. In the pre-segmentation phase, certain regions of the MRI images were designated as either foreground (regions of interest) or background (regions to be ignored). The result of this designation can be seen in Fig. 1B. During the active contour phase, seeds were placed within the regions of interest (foreground), and the seeds were expanded to fill these regions (Fig. 1B). After adequate expansion, user-guided manual tracing was used to correct any errors resulting from automatic segmentation. The final output after manual editing can be seen in Fig. 1C. The 3D-renderings of the segmented brainstems ($N = 55$) are visualized in Fig. 2.

It is important to note that neonatal brain chemistry is different from adults, and resulting T1 contrasts make inter-structure boundaries a challenge to distinguish (Dagia and Ditchfield 2008). In our images, the upper and lower boundaries of the brainstem were not clear and were determined through arbitrary bounds. However, in axial slices of the brainstem (or more precisely, slices perpendicular to its primary axis), extent anteriorly and posteriorly was robustly measurable and reflected the true biological boundary, rather than the limits of imaging contrast. As such, axial slices were used for subsequent shape analyses.

2.4. Summarizing shape

The segmented brainstems were then aligned with each other, so that their shape could be compared. This was done by aligning the segmented surfaces, rather than the original MRI images. In custom code in the Matlab language (Mathworks, Nantick, MA), the marching cubes algorithm was used to identify the surface points of the brainstem volume from the segmentation (Lorensen and Cline 1987). For each brainstem, principal components analysis was then performed on the (x,y,z) coordinates of these surface points, and the first component taken as the primary axis. Brainstems were then rotated to align these primary axes.

In each slice, the anterior and posterior extents were summarized through their maximum within that slice. Two values were thus obtained from each axial position, which can be visualized as a maximum intensity projection in the sagittal profile. These profiles were then registered across subjects with a 3-parameter fit. The parameters were: offset along the principal axis; scaling along the principal axis; anterior/posterior scaling.

To perform automatic registration, these parameters were optimized

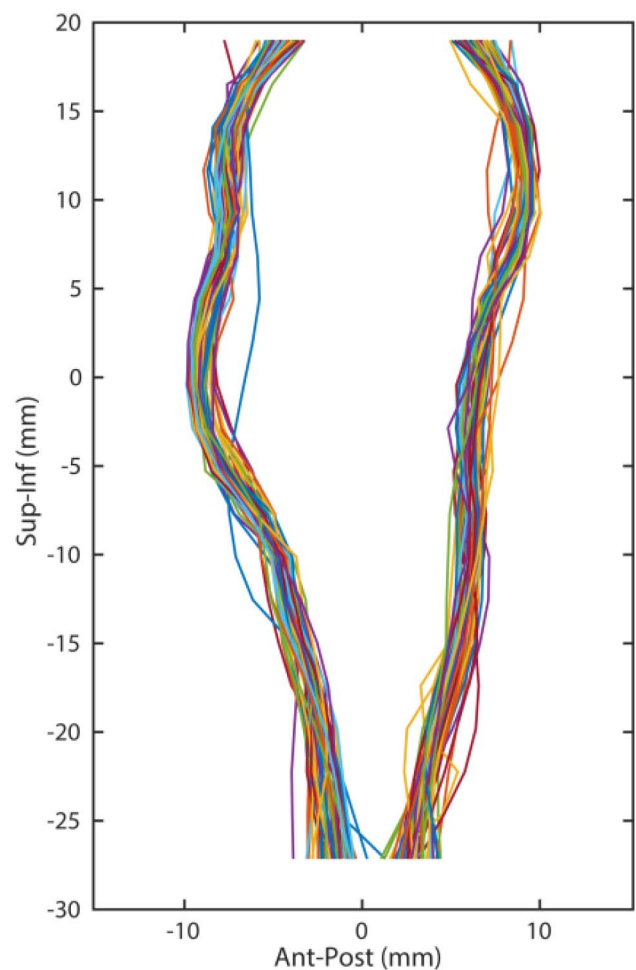


Fig. 3. Registration of all brainstems ($n = 55$) on the principal axis and with a 3-parameter fit.

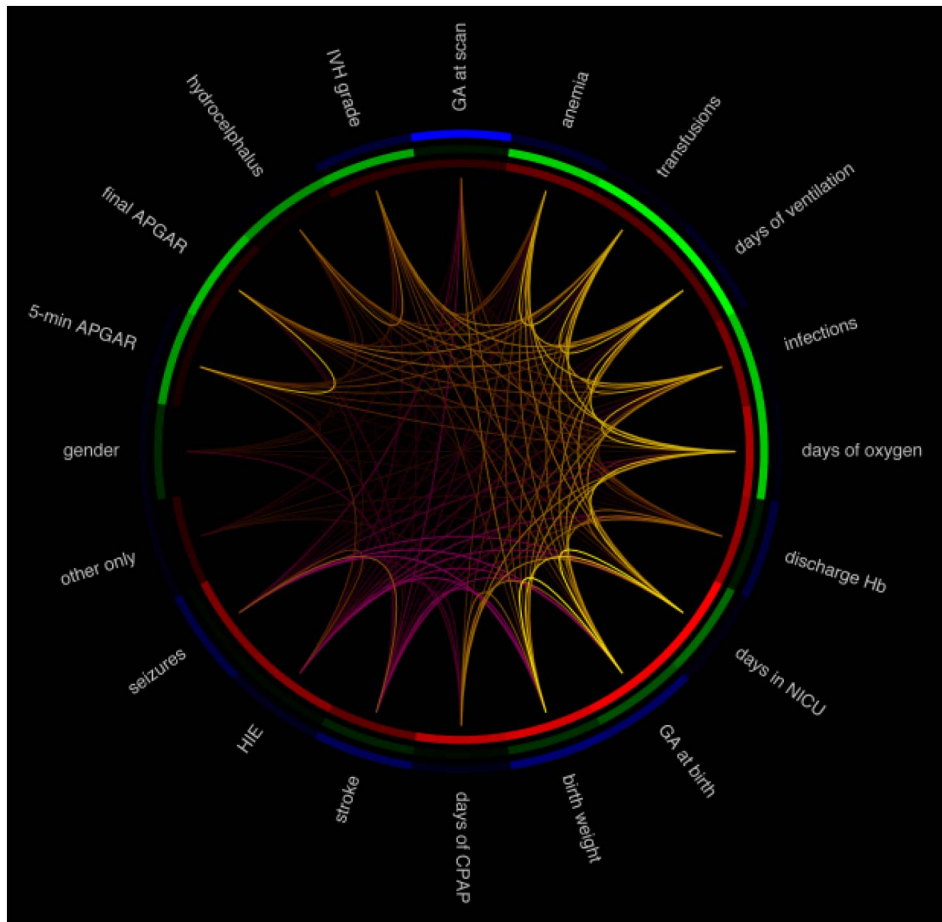


Fig. 4. Correlations between different clinical measures of the clinical course in the NICU. Violet represents negative correlations between measures. Yellow represents positive correlations between measures. (For interpretation of the references to colour in this figure legend, the reader is referred to the web version of this article.)

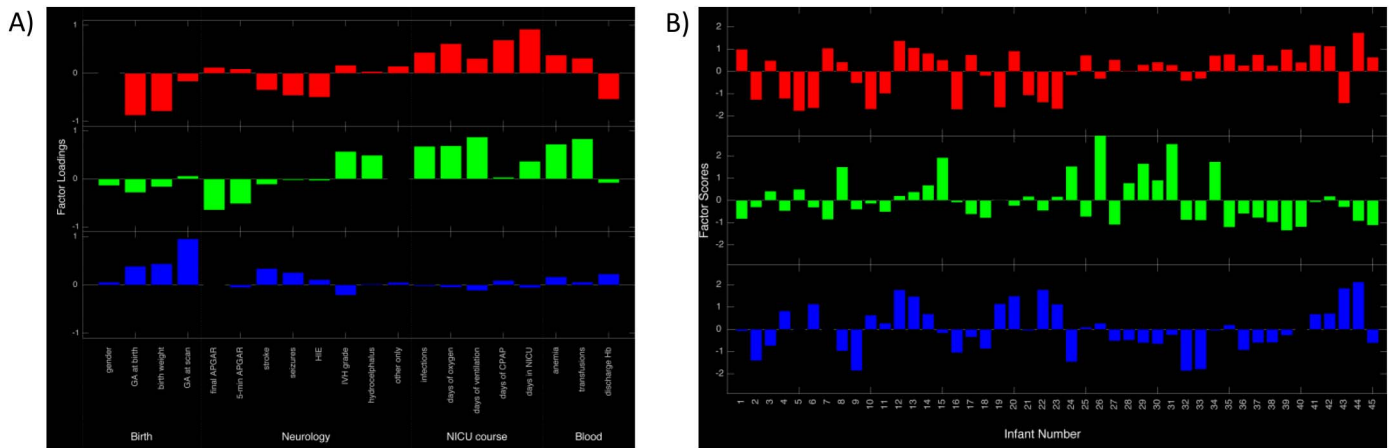


Fig. 5. (A) The 3 factor loadings from factor analysis of clinical course. Clinical factor loadings are numbered in descending order: clinical factor 1 (red), clinical factor 2 (green), clinical factor 3 (blue). (B) The factor scores of the cohort for each clinical factor. (For interpretation of the references to colour in this figure legend, the reader is referred to the web version of this article.)

to minimize the sum of squares deviation between the axial positions of each infant from the mean across infants, using the simplex search method as implemented in Matlab's *fminsearch* command. The resulting aligned brainstem profiles were visualized (Fig. 3). We quantified the quality of the registration (using the inter-subject correlation in shape profile) and conservatively rejected two subjects for whom registration failed, leaving $N = 55$ brainstems.

2.5. Clinical course

The clinical course of each patient was obtained from the discharge summary of the hospital medical records (details in Supplementary Table). Birth characteristics included in factor analysis were gender, GA at birth, GA at scan and birth weight. An Apgar assessment was also performed at 1 and 5 min, and then also at 10 min if the 5-minute score was $< 8/9$, and at 15 min when the requested by the attending clinician. The 5-minute Apgar score and the last Apgar score acquired

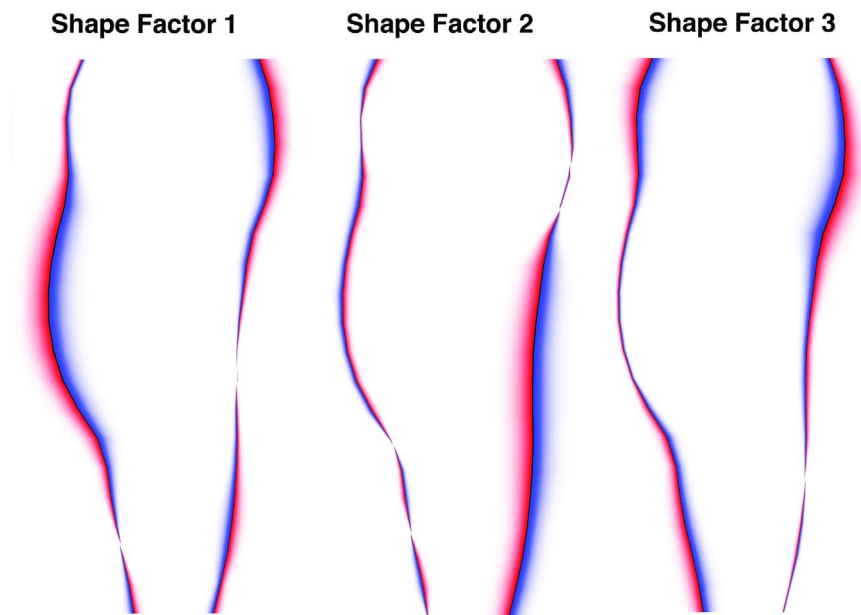


Fig. 6. The 3 shape factors determined from factor analysis of brainstem shape. Red regions depict the shape when more positive for the respective shape factor, while blue regions depict the shape when more negative for the shape factor. (For interpretation of the references to colour in this figure legend, the reader is referred to the web version of this article.)

were included in the birth characteristics. Neurological injuries included were the presence of strokes/seizures/HIE (hypoxic-ischemic encephalopathy), presence of intraventricular hemorrhage (IVH) and grade (I–III, periventricular hemorrhagic infarction), hydrocephalus, and infection. Aspects of the NICU clinical course included were days on oxygen, days on ventilation, days on CPAP (continuous positive airway pressure), and days in the NICU. Aspects related to bloodwork included were presence of anemia, transfusions, and the discharge hemoglobin (Hb).

2.6. Factor analyses and associations between shape and clinical course

Among the clinical courses of our cohort, strong correlations were found among the different clinical measurements (Fig. 4). This suggests the presence of underlying latent factors, which cannot be directly measured, that simultaneously influence multiple clinical measurements. To identify these latent factors, we used the statistical method of factor analysis, a commonly used tool in medical research for performing dimensionality reduction, which identifies a small number of latent factors that explain the major patterns of variation in complex datasets (Jolliffe and Morgan 1992). More specifically, it generates a model that summarizes the complex pattern of variability seen across subjects into a small number of statistically independent underlying factors. Factor analysis was used to generate three clinical factors that summarized the major ways in which clinical course varied across our cohort. The factor loadings (which represent the hidden latent factors) can be seen in Fig. 5A, while the factor scores (how heavily each subject weights on a particular factor loading) can be seen in Fig. 5B.

The anterior and posterior extents were determined in 20 equal slabs along each brainstem's axis, using the robust minimum and maximum of the 5% and 95% points in the distribution of y-coordinates. Since variation in these points is highly correlated (i.e. points from close slabs will vary together), factor analysis was used to summarize shape variation in terms of the points marked along each brainstem's axis. Three shape factors were determined from the registered brainstem profiles in the sagittal plane (Fig. 6).

The relationship between brainstem shape (three factors) and clinical course (three factors) was assessed using Pearson correlation. For significance testing, Bonferroni correction was applied for the nine multiple comparisons. To identify whether any significant associations

are specific to shape, or merely reflect more global factors of brainstem volume or whole-brain volume, we conducted additional analyses on this relationship using partial correlation, while controlling for either brainstem or brain volume.

Finally, while factor analysis is a powerful tool to summarize multivariate data, in a day-to-day clinical context, it is helpful if conclusions can be drawn from single clinical factors. To test whether this was possible in our cohort, we identified the single clinical measure that most strongly weighted onto each of the three clinical factors, and correlated it with each of the three shape factors. We further investigated whether these single clinical measures correlated with the millimeter changes observed in the brainstem.

2.7. Evaluating simpler measures of brainstem shape

In a research setting, factor analysis is a powerful tool that can identify trends within data. However, in a clinical setting, it would be more practical if a radiologist could make a simple measurement directly from an MRI of the brainstem. One aspect that is easily measurable from an MRI is the anterior-posterior width of the brainstem at a given height along its axis. To this end, we determined the height along the vertical axis that correlated most with changes in each of our significant shape factors across individuals, and evaluated these measurements as a proxy for the shape factors.

3. Results

3.1. Factor analyses of shape and clinical course

Shape variation in the different shape factors can be interpreted based on their respective red and blue regions in the rendering (Fig. 6). Red regions depict the shape of the brainstem when more positive for the shape factor, while blue regions depict the shape of the brainstem when more negative for the shape factor. For example, if a certain clinical factor was positively correlated with shape factor 1, that clinical factor would correlate with an enlarged pons (red). Each shape factor was found to weigh most heavily on a particular structure within the brainstem: shape factor 1 weighs most heavily on the pons, shape factor 2 on the posterior medulla, and shape factor 3 on the midbrain (Fig. 6).

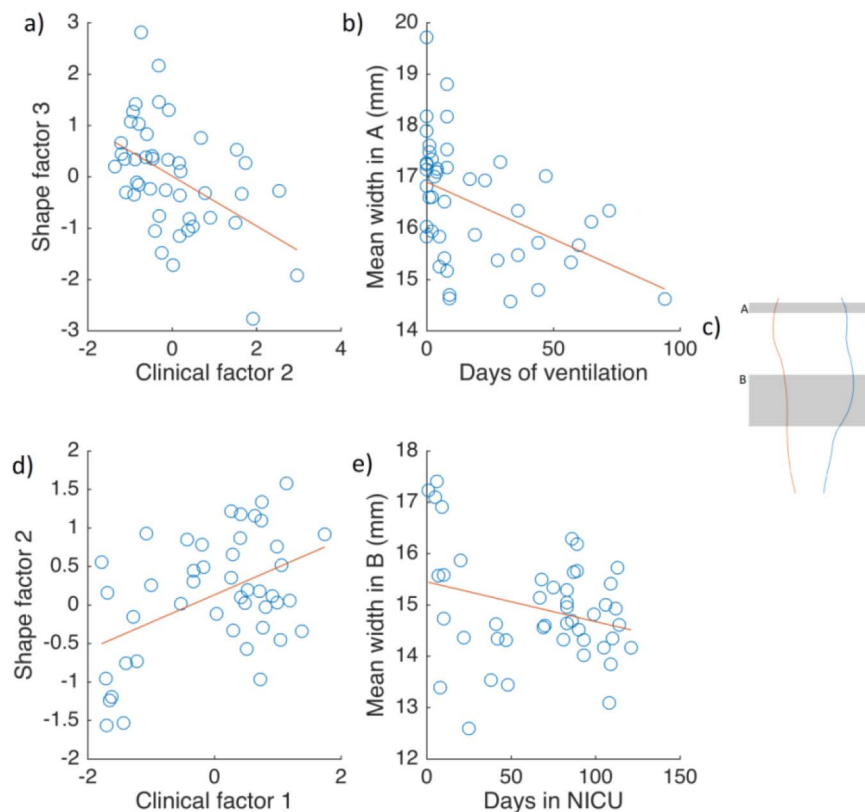


Fig. 7. (A) Correlation between clinical factor 2 and shape factor 3. (B) Correlation between days on ventilation and mean width in region A. (C) Regions of width variation. Region A represents the midbrain, while region B represents the medulla. (D) Correlation between clinical factor 1 and shape factor 2. (E) Correlation between days in NICU and mean width in region B.

The three clinical factor loadings (Fig. 5A) can be interpreted based on their sign and magnitude. Each clinical factor weighs more heavily on particular aspects of the clinical course, and can be interpreted as: (1) low GA (prematurity) and associated complications (2) complications not associated with prematurity; (3) GA at scan. As an example, if a subject was positive for clinical factor 1, the subject would be more premature (lower GA) and have had more clinical interventions (ex. more days on CPAP, more days in the NICU, etc.).

3.2. Correlation between clinical factors and shape factors

Pearson correlation was used to assess the relationship between brainstem shape and clinical course. Two strong relationships were found. Clinical factor 2 negatively correlated with shape factor 3 [Fig. 7A; $r(45) = -0.48, p < 0.01$], indicating that subjects experiencing clinical complications independent of GA had a reduced midbrain. In addition, clinical factor 1 positively correlated with shape factor 2 [Fig. 7D; $r(45) = 0.46, p < 0.05$], indicating that subjects born at a lower GA with associated complications had a reduced posterior medulla. Consequently, we focused on these two shape factors and clinical factors for further analysis.

This relationship of brainstem shape and clinical course is potentially of great importance, but a question of specificity arises. Specifically, could these shape factors merely reflect whole brain volume or brainstem volume? A negative correlation was found between brain volume and brainstem shape factor 2 ($r = -0.41, p = 0.005$). To ensure the shape changes observed were genuine changes in shape, and not reflective of changes in volume instead, we decided to conduct further analyses with brain volume and brainstem volume as covariates.

Clinical factor 2 remained negatively correlated with shape factor 3 when controlling for whole brain volume [$r(45) = -0.48, p < 0.001$]

and brainstem volume [$r(45) = -0.38, p < 0.05$]. Similarly, clinical factor 1 remained strongly positively correlated with shape factor 2 when using partial correlation to control for whole brain volume [$r(45) = 0.55, p < 0.001$] and brainstem volume [$r(45) = 0.46, p < 0.01$]. Thus, these relationships do not reflect changes in overall brain or brainstem size, but instead reflect changes specific to brainstem shape.

Interestingly, 2 correlations became apparent after correction for brainstem volume was performed. A significant negative correlation was found between clinical factor 2 and shape factor 2 [$r(45) = -0.30, p < 0.05$], indicating that subjects experiencing clinical complications independent of GA had a larger posterior medulla. A negative correlation between clinical factor 3 and shape factor 3 [$r(45) = -0.32, p < 0.05$] was also found, indicating that subjects at a higher GA at scan had a reduced midbrain. However, due to the fact that these correlations only became apparent after correcting for brainstem volume, these relationships must reflect changing brainstem size to some extent.

Finally, we calculated whether single clinical measures, representative of the two clinical factors associated with shape, would be directly associated with brainstem shape. The clinical measure most representative of clinical factor 1 was “days in NICU”. This correlated directly with shape factor 2 [$r(45) = 0.42, p < 0.005$], indicating that subjects that had spent more days in the NICU had a smaller posterior medulla. The clinical factor most representative of clinical factor 2 was “days on ventilation”. This correlated directly with shape factor 3 [$r(45) = -0.34, p < 0.05$], indicating that subjects that had spent more days on ventilation had a smaller midbrain.

3.3. Correlating clinical measures with millimeter changes in the brainstem

While relating single clinical measures to shape factors is informa-

tive, it is often helpful in a clinical context if clinical measures can be directly related to raw shape changes in the brainstem. To this end, we correlated the aforementioned single clinical measures to millimeter changes in the width of the relevant brainstem structures – the midbrain and the posterior medulla (Fig. 7C, regions A and B, respectively).

Days of ventilation, summarizing clinical factor 2, negatively correlated with mean anterior-posterior width in the midbrain [Fig. 7B; $r(45) = -0.44$, $p < 0.005$]. Days in the NICU, summarizing clinical factor 1, did not significantly correlate with mean anterior-posterior width in the medulla [Fig. 7E; $r(45) = -0.09$, $p = 0.56$]. Given the failure of this single point measure, as a secondary exploratory analysis, we measured changes in the anterior posterior width averaged over a range of heights (Fig. 7C, region B). This approach showed a trend towards significance [$r(45) = -0.28$, $p = 0.06$], but needs corroboration on an independent dataset.

As a further exploratory analysis, we tested the correlations between the other single clinical measures and each shape factor. Multiple significant correlations were found, and are outlined in the supplementary section.

4. Discussion

In summary, prematurity and its associated complications were correlated with a reduced posterior medulla. Other complications, independent of prematurity, were correlated with a reduced midbrain. The correlations remained highly significant even after correcting for whole brain or brainstem volumes. Moreover, we found that single clinical measures representative of their respective clinical factors correlated with the shape changes. Days on ventilation (summarizing clinical factor 2) linearly associated with changes in the midbrain, and days in the NICU (summarizing clinical factor 1) linearly associated with changes in the posterior medulla. This could provide an estimate of the degree of risk that an infant has brainstem alterations, prior to the acquisition of MRI. Finally, we have applied a number of novel analysis methods to the brainstem – notably the use of principal component analysis to identify its axis, the use of a sagittal maximum intensity projection, the inter-subject registration method, and the use of factor analysis to summarize shape. To our knowledge, this is the first time the effect of the clinical course in the NICU on the shape of the brainstem has been evaluated.

Our study contributes to the understanding of the effects of perinatal insult on the infant brainstem as it goes through its most critical period of development. There is a current paucity of research regarding structural abnormalities in the brainstem in the neonate, attributable to their often fatal effect. Since volumetric alterations have been the main area of focus in the past, shape alterations remain an under-researched topic (Barkovich and Sargent 1995; Mewes et al. 2006; Padilla et al. 2015). Investigating shape differences is of great importance because unlike morphometry, which requires high-contrast MRI data and extensive processing, shape extraction also has the potential for the design of clinical protocols that could be implemented by radiologists. Visually quantifying brain injury via MRI is relatively routine, and the potential of brainstem shape as a biomarker of abnormal development will allow for more accurate diagnosis and early intervention – possibly improving neurodevelopmental outcomes.

Two prior studies have discussed alterations in brainstem shape as a consequence of perinatal insult. Garg et al. (2016) investigated the relationship between brainstem shape and prematurity, and noted inward deformations in the posterior medulla, pons, and posterior midbrain of children 8 years of age born preterm. Our results are in agreement with the finding that a low GA is associated with a reduction in the posterior medulla. In another study, Messerschmidt et al. (2005) investigated cerebellar shape changes due to extreme prematurity, and reported a pattern of reduced sagittal dimensions in the brainstem as well as a flattened anterior curvature of the pons in all their preterm

subjects. This is in accordance with our finding of a correlation between low GA and a reduction in the sagittal projection of the posterior medulla. These two studies, conducted in children 8 years of age and children 2 months–2 years of age, respectively, draw attention to a possible pattern of reductions in the shape of certain brainstem structures as a sequela of prematurity. Taken in conjunction with the results of this study, which also found a correlation between shape reductions and prematurity even at the neonatal age, it is possible that premature birth may disrupt typical brainstem development at the time of birth and mediate shape alterations in the brainstem, with deformities persisting into early childhood. Such a relationship is certainly speculative – further studies are needed to determine a causal relationship.

We did not find a significant correlation between prematurity or perinatal brain injury with shape alterations in the pons. This is contrary to the results of previous studies, which have found reductions in the pons to be a sequela of premature birth and brain injury (Argyropoulou et al., 2003; Garg et al. 2016; Messerschmidt et al. 2005). The discrepancy in results may be attributed to differences in the characteristics of the cohort. In the study conducted by Messerschmidt et al. (2005), almost the entire cohort in question sustained IVH (mostly grades II–IV). In the study conducted by Argyropoulou et al. (2003), all subjects had sustained periventricular leukomalacia. Garg et al. (2016) examined shape differences in a preterm-born cohort at school age, but there was no mention of previous perinatal brain injury sustained by the cohort. In this study, the cohort was highly heterogeneous, varying in terms of GA as well as neurological injury, which may explain why we did not find a significant correlation with the NICU clinical course and shape alterations in the pons.

Although the single clinical measure most representative of clinical factor 2 directly correlated with millimeter change in midbrain width, the clinical measure summarizing clinical factor 1 did not significantly correlate to millimeter change in the medulla. This exemplifies the complex relationship between clinical course and brainstem shape, and reiterates the utility of factor analysis, which revealed changes in brainstem shape that single clinical measurements did not. Further work towards a clinically applicable measure of changes in brainstem shape would need to identify neuroanatomical landmarks that can be used to accurately define the height at which measurements should be made, rather than relying on image registration.

We acknowledge that semi-quantitative post-processing of MRI images is quite cumbersome, and were interested in whether the changes in brainstem shape were visible by qualitative evaluation of the raw MRI images. To test this, we examined the MRI images from a few subjects at the positive and negative extremes of clinical factor 1 and 2. While some minor changes to the anterior-posterior extents of the posterior medulla and midbrain could be observed by visual examination, these changes were subtle and we believe qualitative assessment should be interpreted with caution. Brainstems are varied in their lengths and widths, which makes shape changes difficult to subjectively quantify, even for the subjects at the extremes of their clinical factors.

While a biological interpretation of shape changes in the brainstem and how they relate to neurological function would be clinically useful, such interpretations are difficult to make. Although the present study identified regional shape changes in the brainstem in terms of their anterior-posterior extents, these shape changes are global to their respective regions and not specific to any substructures within that region. This represents one limitation to using factor analysis to summarize shape changes, as the shape changes are too general to infer specific related functional sequelae. With these difficulties in mind, it is still possible to speculate about possible functional consequences that may result from regional shape changes in the brainstem by relating structure to function. Narrowing of the anterior-posterior extents probably reflects atrophy in the respective regions, and any functional sequelae that might be seen will most likely be related to

degeneration within these areas.

Beginning with the midbrain, the midbrain can be roughly divided posteriorly and anteriorly into the tectum and cerebral peduncles, respectively, with the tectum being further subdivided into the superior and inferior colliculi. Briefly, the superior colliculus has an important role in vision and visually-guided behavior (such as head/eye orientation to environmental stimuli), while the inferior colliculus is involved in audition and sound-related behavior (Wurtz and Albano 1980; Xiong et al. 2015). The cerebral peduncles connect the brainstem to the cerebrum, and many of the fiber tracts that pass through the cerebral peduncles are important for motor control. Functional consequences related to the correlation between clinical factor 2 (complications independent of GA) and a reduction in the midbrain may plausibly affect any of the aforementioned functions. The medulla oblongata is implicated in the regulation of many autonomic functions, and also plays a role in motor function, with motor fibers of the corticospinal tract passing through this brainstem structure. Functional consequences related to the correlation between clinical factor 1 (low GA and associated complications) and a narrowing of the posterior medulla may possibly impact the aforementioned functions. In fact, a previous study found a significant association between medullary width and motor score as assessed by the Neonatal Behavioral Assessment Scale (Sanz-Cortes et al. 2014).

However, it is important to keep in mind that patients with midbrain and hindbrain malformations have been reported to present with non-specific symptoms, and also have a wide range of neurodevelopmental outcomes (Doherty et al. 2013). This reiterates the complexity of predicting functional consequences that may result from structural changes in the brain. Future studies that investigate specific functional consequences that result from certain structural alterations, as well as possible biological mechanisms, will be of immense clinical value. Early intervention is beneficial to neurodevelopmental outcome, and studies that successfully relate functional sequelae to structural alterations will allow for targeted interventions.

A limitation of this study is that longitudinal follow-up is not available to characterize the neurodevelopmental consequences of changes in brainstem shape. Another weakness is that the sample size is not sufficient to allow investigation into whether the patterns of brainstem shape changes were different within subgroups of distinct pathology. Finally, our shape analysis was limited to the brainstem, but other structures (such as the cerebellum) may also be affected. The cerebellum and brainstem are tightly linked not only structurally, but functionally as well. For example, while the brainstem contributes to the initiation of movement, the cerebellum works in tandem to fine-tune the movement. To illustrate this point, a recent study found that both medullary width as well as cerebellar width were significantly associated to motor scores assessed by the Neonatal Behavioral Assessment Scale (Sanz-Cortes et al. 2014). We agree that shape changes in the cerebellum are important to consider as well, and our future projects will investigate this topic further.

An important contribution of our work is to show that while NICU complications and different gestational ages both affected the brainstem, they did so in different ways, correlating with different aspects of shape. This might mediate some of the distinct neurodevelopmental profiles seen in these groups. Moreover, we were able to find a common structure affected by different perinatal insults.

5. Conclusions

Using structural MRI at term-equivalent age in a heterogeneous sample of NICU neonates at risk of neurodevelopmental delays, we found that GA and associated complications, and complications independent of GA, affected the shape of the brainstem – with alterations seen in the posterior medulla and midbrain, respectively. These structural changes in this critical brain system may have many neurodevelopmental consequences.

Acknowledgements

This work was supported by the Canada Excellence Research Chair (CERC) in Cognitive Neuroimaging, a Natural Sciences and Engineering Research Council of Canada (NSERC) Discovery Grant (NSERC 418293DG-2012), CIHR/NSERC Collaborative Health Research Project (CHRP 201110CPG).

Appendix A. Supplementary data

Supplementary data to this article can be found online at <http://dx.doi.org/10.1016/j.nicl.2017.04.007>.

References

- Argyropoulou, M.I., Xydis, V., Drougia, A., Argyropoulou, P.I., Tzoufi, M., Bassounas, A., Andronikou, S., Efremidis, S.C., 2003. MRI measurements of the pons and cerebellum in children born preterm; associations with the severity of periventricular leukomalacia and perinatal risk factors. *Neuroradiology* 45, 730–734. <http://dx.doi.org/10.1007/s00234-003-1067-0>.
- Barkovich, A.J., Sargent, S.K., 1995. Profound asphyxia in the premature infant: imaging findings. *Am. J. Neuroradiol.* 16, 1837–1846.
- Berntson, G.G., Micco, D.J., 1976. Organization of brainstem behavioral systems. *Brain Res. Bull.* 1, 471–483. [http://dx.doi.org/10.1016/0361-9230\(76\)90117-9](http://dx.doi.org/10.1016/0361-9230(76)90117-9).
- Cohen, M.I., 1979. Neurogenesis of respiratory rhythm in the mammal. *Physiol. Rev.* 59, 1105–1173.
- Dagia, C., Ditchfield, M., 2008. 3T MRI in paediatrics: challenges and clinical applications. *Eur. J. Radiol.* 68, 309–319. <http://dx.doi.org/10.1016/j.ejrad.2008.05.019>.
- Darnall, R.A., Ariagno, R.L., Kinney, H.C., 2006. The late preterm infant and the control of breathing, sleep, and brainstem development: a review. *Clin. Perinatol.* 33, 883–914.
- Doherty, D., Millen, K.J., Barkovich, J.A., 2013. Midbrain-hindbrain malformations: advances in clinical diagnosis, imaging, and genetics. *Lancet Neurol.* 12, 381–393. <http://dx.doi.org/10.1016/j.immuni.2010.12.017>.
- Drew, T., Prentice, S., Schepens, B., 2004. Cortical and brainstem control of locomotion. pp. 251–261. doi:[http://dx.doi.org/10.1016/S0079-6123\(03\)43025-2](http://dx.doi.org/10.1016/S0079-6123(03)43025-2).
- Garg, A., Grunau, R.E., Popuri, K., Miller, S., Bjornson, B., Poskitt, K.J., Beg, M.F., 2016. Surface displacement based shape analysis of central brain structures in preterm-born children. *SPIE Med. Imaging* 9788, 97880H. <http://dx.doi.org/10.1117/12.2216914>.
- Geva, R., Feldman, R., 2008. A neurobiological model for the effects of early brainstem functioning on the development of behavior and emotion regulation in infants: implications for prenatal and perinatal risk. *J. Child Psychol. Psychiatry* 49, 1031–1041. <http://dx.doi.org/10.1111/j.1469-7610.2008.01918.x>.
- Guertzenstein, P.G., Silver, A., 1974. Fall in blood pressure produced from discrete regions of the ventral surface of the medulla by glycine and lesions. *J. Physiol.* 242, 489–503.
- Hobson, J.A., McCarley, R.W., Wyzinski, P.W., 1975. Sleep cycle oscillation: reciprocal discharge by two brainstem neuronal groups. *Science* 189, 55–58.
- Hüppi, P.S., Warfield, S., Kikinis, R., Barnes, P.D., Zientara, G.P., Jolesz, F.A., Tsuiji, M.K., Volpe, J.J., 1998. Quantitative magnetic resonance imaging of brain development in premature and mature newborns. *Ann. Neurol.* 43, 224–235. <http://dx.doi.org/10.1002/ana.410430213>.
- Jiang, Z.D., Brosi, D.M., Chen, C., Wilkinson, A.R., 2009. Impairment of perinatal hypoxia-ischemia to the preterm brainstem. *J. Neurol. Sci.* 287, 172–177. <http://dx.doi.org/10.1016/j.jns.2009.07.029>.
- Jiang, Z., Brosi, D., Yin, R., Wilkinsin, A.R., 2012. Term neonates receiving intensive care at high risk of brainstem auditory impairment. *Arch. Dis. Child. Fetal Neonatal Ed.* 97, F359–F361. <http://dx.doi.org/10.1136/fetalneonatal-2011-301200>.
- Jiang, Z.D., Zhou, Y., Yin, R., Wilkinson, A.R., 2013. Amplitude reduction in brainstem auditory response in term infants under neonatal intensive care. *Clin. Neurophysiol.* 124, 1470–1476. <http://dx.doi.org/10.1016/j.clinph.2013.02.009>.
- Jolliffe, I.T., Morgan, B.J.T., 1992. Principal component analysis and exploratory factor analysis. *Stat. Methods Med. Res.* 1, 69–95.
- Lorenson, W.E., Cline, H.E., 1987. Marching cubes: a high resolution 3D surface construction algorithm. *ACM SIGGRAPH Comput. Graph.* 21, 163–169. <http://dx.doi.org/10.1145/37402.37422>.
- Messerschmidt, A., Brugger, P.C., Boltshauser, E., Zoder, G., Sterniste, W., Birnbacher, R., Prayer, D., 2005. Disruption of cerebellar development: potential complication of extreme prematurity. *Am. J. Neuroradiol.* 26, 1659–1667.
- Messerschmidt, A., Prayer, D., Brugger, P.C., Boltshauser, E., Zoder, G., Sterniste, W., Pollak, A., Weber, M., Birnbacher, R., 2008. Preterm birth and disruptive cerebellar development: assessment of perinatal risk factors. *Eur. J. Paediatr. Neurol.* 12, 455–460. <http://dx.doi.org/10.1016/j.ejpn.2007.11.003>.
- Mewes, A.U.J., Hüppi, P.S., Als, H., Rybicki, F.J., Inder, T.E., McNulty, G.B., Mulker, R.V., Robertson, R.L., Rivkin, M.J., Warfield, S.K., 2006. Regional brain development in serial magnetic resonance imaging of low-risk preterm infants. *Pediatrics* 118, 23–33. <http://dx.doi.org/10.1542/peds.2005-2675>.
- Nosarti, C., Giouroukou, E., Healy, E., Rifkin, L., Walshe, M., Reichenberg, A., Chitnis, X., Williams, S.C.R., Murray, R.M., 2008. Grey and white matter distribution in very preterm adolescents mediates neurodevelopmental outcome. *Brain* 131, 205–217.

- <http://dx.doi.org/10.1093/brain/awm282>.
- Nosarti, C., Nam, K.W., Walshe, M., Murray, R.M., Cuddy, M., Rifkin, L., Allin, M.P.G., 2014. Preterm birth and structural brain alterations in early adulthood. *NeuroImage. Clin.* 6, 180–191. <http://dx.doi.org/10.1016/j.nicl.2014.08.005>.
- Padilla, N., Alexandrou, G., Blennow, M., Lagercrantz, H., Adén, U., 2015. Brain growth gains and losses in extremely preterm infants at term. *Cereb. Cortex* 25, 1897–1905. <http://dx.doi.org/10.1093/cercor/bht431>.
- Payne, A.H., Hintz, S.R., Hibbs, A.M., Walsh, M.C., Vohr, B.R., Bann, C.M., Wilson-Costello, D.E., 2013. Neurodevelopmental outcomes of extremely low-gestational-age neonates with low-grade periventricular-intraventricular hemorrhage. *JAMA Pediatr.* 167, 451–459. <http://dx.doi.org/10.1001/jamapediatrics.2013.866>.
- Sanz-Cortes, M., Egaña-Ugrinovic, G., Zupan, R., Figueras, F., Gratacos, E., 2014. Brainstem and cerebellar differences and their association with neurobehavior in term small-for-gestational-age fetuses assessed by fetal MRI. *Am. J. Obstet. Gynecol.* 210, 1–8. <http://dx.doi.org/10.1016/j.ajog.2013.12.008>.
- Vohr, B.R., Wright, L.L., Dusick, A.M., Mele, L., Verter, J., Steichen, J.J., Simon, N.P., Wilson, D.C., Broyles, S., Bauer, C.R., Delaney-Black, V., Yolton, K.A., Fleisher, B.E., Papile, L.A., Kaplan, M.D., 2000. Neurodevelopmental and functional outcomes of extremely low birth weight infants in the National Institute of Child Health and Human Development Neonatal Research Network, 1993-1994. *Pediatrics* 105, 1216–1226. <http://dx.doi.org/10.1542/peds.105.6.1216>.
- White, T.P., Symington, I., Castellanos, N.P., Brittain, P.J., Froudust Walsh, S., Nam, K.-W., Sato, J.R., Allin, M.P.G., Shergill, S.S., Murray, R.M., Williams, S.C.R., Nosarti, C., 2014. Dysconnectivity of neurocognitive networks at rest in very-preterm born adults. *NeuroImage. Clin.* 4, 352–365. <http://dx.doi.org/10.1016/j.nicl.2014.01.005>.
- Wurtz, R.H., Albano, J.E., 1980. Visual-motor function of the primate superior colliculus. *Annu. Rev. Neurosci.* 3, 189–226.
- Xiong, X.R., Liang, F., Zingg, B., Ji, X., Ibrahim, L.a., Tao, H.W., Zhang, L.I., 2015. Auditory cortex controls sound-driven innate defense behaviour through corticofugal projections to inferior colliculus. *Nat. Commun.* 6, 7224. <http://dx.doi.org/10.1038/ncomms8224>.
- Yushkevich, P.a., Piven, J., Hazlett, H.C., Smith, R.G., Ho, S., Gee, J.C., Gerig, G., 2006. User-guided 3D active contour segmentation of anatomical structures: significantly improved efficiency and reliability. *NeuroImage* 31, 1116–1128. <http://dx.doi.org/10.1016/j.neuroimage.2006.01.015>.